

Comparative Morphometric Study of the Optic Nerve in One-Humped Camel (*Camelus dromedarius*) and Donkey (*Equus asinus*)

Ihab El-Zoghby¹ and ² Ahmed Kassab

¹ Department of Histology and Cytology & ² Department of Anatomy and Embryology Faculty of Veterinary Medicine, Benha University (Moshtohor), Egypt.

With 8 figures and 2 tables

Received July, accepted for publication August 2010

Abstract

Comparative anatomical studies were made measuring several morphological characteristics seen in cross-sections of the optic nerve of one-humped camel (*Camelus dromedarius*) and donkey (*Equus asinus*). Six optic nerves from each animal were used in this study. The optic nerve samples were obtained about 5mm behind the eye. The axon numbers and diameters were studied with light and transmission electron microscopes. Axon diameters were measured in samples of 500 axons taken from several locations in a cross section of the optic nerve behind the eye. The total cross-sectional area of the optic nerve was about 35% smaller in the donkey than in the camel. The fibers are organized in fascicles. The fiber density and number was 2.3 times higher in the camel than in the donkey. The total number of optic nerve

fibers counted was 1173323 ± 33039 in camels and 495754 ± 10126 in donkeys. The majority of axons were myelinated in the optic nerve of both animals. There was a significant regional variation in the size of optic nerve axons. Large myelinated axons were observed in the dorsal and ventral periphery, whereas smaller myelinated fibers and a high proportion of unmyelinated fibers were found in the center of the nerve.

Key words

Camel, Donkey, Optic Fibers, Morphometry.

Introduction

The optic nerve, which acts like a cable, transmits electrical impulses from the retina to the brain. The optic nerve is a continuation of the axons of the ganglion cells of the retina. The anatomy and topography

of the optic nerve have attracted the attention of many investigators in recent years. The total number and sizes of the optic axons have been studied intensively in cats (Donovan 1967; Boycott & Wassle, 1974; Hughes & Wassle 1976; Freeman, 1978 and Stone & Champion, 1978), dogs (Hogan & Williams, 1995), rabbits (Hughes, 1971 and Vaney & Hughes, 1976), monkeys (Sanchez et al., 1986; Reese & Ho, 1988) and humans (Mikelberg et al., 1989 and Jonas et al., 1992). There are only a few studies of the optic tract in Indian buffaloes, ponies, cows, sheep, pigs and horses (Tewari & Rao, 1975; Herron et al., 1978; Guo, et al., 2001). However, there is no study on the optic nerve in camels and donkeys. The study of the number and size of optic axons is important in understanding the functional aspects of the optic nerve.

The objectives of the present study were first, to provide an accurate count of the total number of optic nerve fibers by using light and transmission electron microscopy and second, to study the topography and distribution of axon diameters in the center and periphery of a cross-section of the optic nerve.

Materials and Methods

Six optic nerves from both adult healthy one-humped camel (*Camelus dromedarius*) and donkey (*Equus asinus*) were examined in the present study (three rights and three left). The specimens of camels were obtained after slaughtering from Benha slaughterhouse in Egypt. While the donkey optic nerves were obtained from the anatomy room in the faculty of Veterinary Medicine, Benha University. The eyeballs and optic nerves were immersed in 10% formaldehyde solution with a phosphate buffer (pH7.4). The orientation of the optic nerve was determined before its removal from the eyeball by putting marks on the dorsal and lateral surfaces. The dural sheath was removed and the optic nerves were cut transversely into 1-2 mm thick parts at different levels (6-20 mm) posterior to the eyeball. Each optic nerve cross-section was subdivided into nine parts of roughly equal area.

For light microscopy, the specimen was dehydrated and embedded in paraffin. Sections of 5-6 μm in thickness were obtained and stained with haematoxylen and eosin according to the methods given by Bancroft et al., (1994).

For electron microscopy, the optic nerves were fixed in 2.5% glutaraldehyde solution with 0.1 mol/L phosphate buffer (pH 7.4) for 24-48 h, postfixed in 2% osmic acid for 2 h, then dehydrated in ascending grades of alcohol and immersed in propylene oxide. Finally, they were embedded in Epoxy resin. The block was polymerized for 24 h at 70°C. Semithin sections (0.4 μm) were cut with glass knives on an ultramicrotome and stained with 0.3% toluidine blue. To estimate the total number of the optic fibers, the sections were photographed at magnification X200. About 10 photos were taken for each area. The fibers were counted from the photos with the aid of graticule (3.9x3.9 mm). The graticule marked an area on the optic nerve of 0.05 x 0.05 mm^2 . The nerve fibers within this square and touching the left and lower margins were counted. The area of the cross-section of the optic nerve was measured through the computer by scanning the optic nerve, then drawing the outline of the optic nerve. The total area containing axon bundles was measured using area properties software of image analysis (SemAfore software). The total number of fibers was estimated by proportionality.

Ultrathin sections (70 nm) were cut, mounted on copper mesh grids (No. 200) and stained with saturated so-

lution of uranyl acetate dihydrate. The sections were examined with a JEOL-100SX Electron Microscope. Ninety micrographs were taken with the aid of a mesh window. The electron micrographs were regularly taken at magnifications of X2000 and X2500 and photographically enlarged at X2. The final magnifications were X4000 and X5000. The precise magnification was determined with the aid of a calibration grid. The diameters of myelinated and unmyelinated axons were measured from the micrographs using area properties software of image analysis. The diameters of 500 axons were measured from the whole cross-section area of the optic nerve. These axons were classified into three groups according to their size (Williams & Chalupa, 1983). The myelin sheath was not included in the measurements. The transmission electron microscopy was made in Almaza Military Veterinary Hospital.

Results

The optic nerve

The optic nerve of the camel and donkey was circular in shape in the cross-section and the mean diameter of the cross-sectional area was 25.2 ± 0.84 for camels and about 18.4 ± 0.79 mm^2 for donkeys.

The optic fibers gathered together into bundles or fascicles of different sizes and shapes (Fig. 1). These bundles or fascicles were demarcated from each other by glial processes, fibroblasts, collagen fibers and blood vessels as seen by the light microscope (Fig. 1 and 2). The optic fibers of different diameters appeared clearly under a high magnification of the light microscope (Fig. 3 and 4). Under the electron microscope, the optic fibers were mostly myelinated and a very small number of unmyelinated nerve fibers were observed (Fig. 5 and 6) of both animals.

The total number of optic fibers

The total number of optic nerve fibers counted was 1173323 ± 33039 in camels and 495754 ± 10126 in donkeys (Table 1 and 2). Although there was little difference in the distribution of the fibers in the different areas of the optic nerve, the density of the fibers was slight higher dorsally than ventrally. The highest density of optic fibers was in the dorso-temporal area of the cross-section of the optic nerve. While the lowest density was in the ventro-nasal areas, where the large axons could be observed.

The axon diameters

The diameters of the optic axons were measured in samples from

nine regions of the optic nerve. Five hundred axons from camels and donkeys were measured to study the axon diameter. Histograms of the frequency of axon diameters in the optic axons are shown in Fig (7 and 8). Axon diameter was the lowest in the dorso-temporal (mean, $2.8 \mu\text{m}$) part of the optic nerve and the highest in the ventro-temporal (mean, $4.7 \mu\text{m}$) and ventro-nasal parts of the optic nerve (average, $3.3 \mu\text{m}$).

As shown in Fig. (7 and 8) the overall diameters of the optic axons ranged from 0.6 to $14.3 \mu\text{m}$ and the peak diameters ranged from 2.0 to $3.5 \mu\text{m}$. Axons of small and medium diameters were numerous in all areas of the optic nerve. The large optic axons were few in number and were observed in the ventro-temporal and ventro-nasal parts of the optic nerve.

According to the present results, the optic axons could be classified into small axons between 0.5 and $2.5 \mu\text{m}$, intermediate sized axons between 2.5 and $7.0 \mu\text{m}$ and large axons with a diameter $> 7.0 \mu\text{m}$ (7.0 - $12.3 \mu\text{m}$).

The fiber diameters

The optic fiber is composed of the optic axon and the myelin sheath. Diameters of 500 fibers were also measured in the camel and donkey

optic nerves. The diameters of the optic fibers ranged from 1.1 to 16.0 μm .

Discussion

The present work is a pioneer study of the optic nerve of camels and donkeys. The optic nerve of the camel has a large cross-sectional area (25.20 mm^2), about 10 times larger than the optic nerve in cats (1.80 mm^2 , Hughes & Wassle, 1976), rabbits (1.20 mm^2 , Vaney & Hughes, 1976), tree shrews (1.90 mm^2 , Drenhaus et al., 1997) and monkeys (5.94 mm^2 , Sanchez et al., 1986). The cross-sectional area of the donkey optic nerve in the present study is smaller than that of camel but simulates that of the horse (Guo et al., 2001). There is no previous report about the area of the optic nerve in large animals like cattle. The large area of the optic nerve of camels might be due to the large number and size of optic fibers that come from the ganglion cells of the retina and form the optic nerve.

The present estimates of the optic fibers of camels by light and electron microscopes were 1173323. These were higher than in humans (969 000, Potts et al., 1972; 1 200 000, Mikelberg et al., 1989); cats (120 000, Bishop et al., 1953; 194 000, Hughes & Wassle, 1976; 128

000, Stone & Campion, 1978); dogs (148 303, Brooks et al., 1995); rabbits (394 000, Vaney & Hughes, 1976) and rats (118 000, Forrester & Peters, 1967). However, this number is less than that in rhesus monkeys (1 700 000, Potts, et al., 1972) and pigeons (2 379 000. Binggeli & Paul, 1969). There was previously estimated the total number of ganglion cells on the whole mount retina of the camel to be around one million (Harman et al., 2001). So the number of optic fibers counted in this study in the camel corresponds to the total number of ganglion cells in the retina of camels (Harman et al., 2001).

The total number of optic fibers may differ according to the technique used (Sanchez et al., 1986). To provide an accurate count of the number of the fibers and to avoid any discrepancy, we used light and electron microscopes to count the number of optic fibers and the specimens were taken from different levels behind the optic disc. Fewer optic fibers were counted by light microscope than by electron microscope. This discrepancy in the number of optic fibers between light and electron microscopes was due to difficulty counting the small myelinated and unmyelinated nerve fibers by the light microscope. Thus, the number of optic fibers counted

by electron microscope should be more accurate.

Most of the optic fibers observed in this study were myelinated, similar to the reports in rabbits (Vaney & Hughes, 1976), cats (Friede, et al. 1971 and Williams & Chalupa, 1983) and primates (Potts et al. 1972; Reese & Ho, 1988). On the other hand, Dunlop et al. (1994) observed that 26-43% of the optic axons in the honey possum are unmyelinated.

The size of axons in the optic nerve of camels and donkeys, 0.5-12.3 μm , is nearly similar to that reported in cats (0.5-13.5 μm , Hughes & Wassle, 1976) and larger than that recorded in primates (0.25-2.50 μm , Potts et al., 1972) and rabbits (0.25-7.00 μm , Vaney & Hughes, 1976). Our finding of large optic axons in the ventro-nasal and ventro-temporal parts of the optic nerve is consistent with previous finding of large ganglion cells in the ventral part of the retina in horses (Hebel, 1976 and Guo et al., 2001), in goat (Hughes and Whittereridge, 1973) and in cat (Fukuda et al., 1985).

References

- Bancroft, J. D.; Cook, H. C.; Stirling, R. W. and Turner, D. R. (1994): Manuel of histological techniques and their diagnostic application. 2ed. Churchill Livingston, Edinburgh, London, Madrid, Melbourne, New York, and Tokyo.
- Binggeli, R. L. and Paul, W. J. (1969): The pigeon retina: quantitative aspects of the optic nerve and ganglion cell layer. *Journal of Comparative Neurology* 137, 1-18.
- Bishop, P. O.; Jeremy, D. and Lance, J. W. (1953): The optic nerve: Properties of a central tract. *Journal of Physiology* 121, 415-432.
- Boycott, B. B. and Wassle, H. (1974): The morphological types of ganglion cells of the domestic cat's retina. *Journal of Physiology* 240, 397-419.
- Brooks, D. E.; Strubbe, D. T.; Kubilis, P. S.; MacKay, E. O.; Samuelson, D. A. and Gelatt, K.N.(1995): Histomorphometry of the optic nerves of normal dogs and dogs with hereditary glaucoma. *Exp Eye Res.* 60(1):71-89.
- Donovan, A. (1967): The nerve fiber composition of the cat optic nerve. *J. Anat.* 101, 1-11.
- Drenhaus, U.; Gunten, A. V. and Rager, G. (1997): Classes of axons and their distribution in the optic nerve of the tree shrew (*Tupaia belangeri*). *Anat. Rec.* 249, 103-116.
- Bancroft, J. D.; Cook, H. C.; Stirling, R. W. and Turner, D. R. (1994): Manuel of histological techniques and their diagnostic application. 2ed. Churchill Livingston, Edinburgh, London, Madrid, Melbourne, New York, and Tokyo.

- Dunlop, S. A.; Ross, W. M. and Beazley, D. (1994): The retinal ganglion cell layer and optic nerve in a marsupial, the honey possum (*Tarsipes rostratus*). *Brain, Behavior and Evolution* 44, 307-323.
- Forrester, J. and Peters, A. (1967): Nerve fibers in optic nerve of rat. *Nature* 214, 245-247.
- Freeman, B. (1978): Myelin sheath thickness and conduction latency groups in the cat optic nerve. *Journal of Comparative Neurology* 181, 183-196.
- Friede, R. L.; Miyagishi, T. and Hu, K. (1971): Axon caliber, neuro-filaments, microtubules, sheath thickness and cholesterol in cat optic nerve fibers. *J. Anat.* 108, 365-373.
- Fukuda, Y.; Hsiao, C. F.; Watanabe, M. and Ito, H. (1985): Morphological correlates of physiologically identified Y-, X-, and W-cells in cat retina. *Journal of Neurophysiology*. 52, 999-1013.
- Guo Xiaoli, Masato Aoyama and Shoei Sugita (2001): Quantitative analysis of the optic nerve of the horse (Thoroughbred). *J. Vet. Med. Sci.* 63 (9): 971-975
- Harman Alison; Jody Dann; Alicia Ahmat; Todd Macuda; Kevin Johnston and Brian Timneyb (2001): The Retinal Ganglion Cell Layer and Visual Acuity of the Camel. *Brain Behav Evol* 58:15-27
- Hebel, R. (1976): Distribution of retinal ganglion cells in five mammalian species (pig, sheep, ox, horse, and dog). *Anat. and Embryol.* 150, 45-51.
- Herron, A.; Martin, E. and Joyce, R. (1978): Quantitative study of the decussating optic axons in the pony, cow, sheep and pig. *Amer. J. of Vet. Res.* 39, 1137-1139.
- Hogan, D. and Williams, R. W. (1995): Analysis of the retinas and optic nerves of achiasmatic Belgian sheep dogs. *Journal of Comparative Neurology* 352, 367-380.
- Hughes, A. (1971): Topographical relationships between the anatomy and physiology of the rabbit visual system. *Documenta Ophthalmologica* 30, 33-159.
- Hughes, A. and Wassle, H. (1976): The cat optic nerve: Fiber total count and diameter spectrum. *Journal of Comparative Neurology* 169, 171-184.
- Hughes, A. and Whitteridge, D. (1973): The receptive fields and topographical organization of goat retinal ganglion cells. *Vision Research* 13, 1101-1114.
- Jonas, J. B.; Schmidt, A. M.; Müller-Bergh, J. A.; Schlotzer-Schrehardt, U. M. and Naumann, G. O. (1992): Human optic nerve fi-

- ber count and optic disc size. *Investigative Ophthalmology and Visual Science* 33, 2012-2018.
- Mikelberg, F. S.; Drance, S. M.; Schulzer, M.; Yidegiligne, H. M. and Weis, M. M.(1989): The normal human optic nerve: Axon count and axon diameter distribution. *Ophthalmology*. 96 (9) : 1325-8.
- Potts, A. M.; Hodges, D.; Shelman, C. B.; Fritz, K. J.; Levy, N. S. and Mangnall, Y.(1972): Morphology of the primate optic nerve. I. Method and total fiber count. *Invest Ophthalmol*. 11(12):980-8.
- Reese, B. E. and Ho, K. Y. (1988): Axon diameter distributions across the monkey's optic nerve. *Neuroscience*. 27(1):205-14.
- Sanchez, R. M.; Dunkelberger, G. R. and Quigley, H. A. (1986): The number and diameter distribution of axons in the monkey optic nerve. *Invest Ophthalmol Vis Sci*. 27(9):1342-50.
- Stone, J. and Champion, J. E. (1978): Estimate of the number of myelinated axons in the cat's optic nerve. *J Comp Neurol*. 15; 180(4):799-806.
- Tewari, A. N. and Rao, G. S. (1975): Anatomical studies on the optic tract (tractus opticus) of the Indian buffalo (*Bubalus bubalis*). *Anat Anz*. 138(5):392-7.
- Vaney, D. I. and Hughes, A. (1976): The rabbit optic nerve: fiber diameter spectrum, fiber count, and comparison with a retinal ganglion cell count. *J Comp Neurol*. 15; 170(2):241-51.
- Williams, R. W. and Chalupa, L. M. (1983): An analysis of axon caliber within the optic nerve of the cat: evidence of size groupings and regional organization. *J. Neurosci*. 3(8):1554-64.

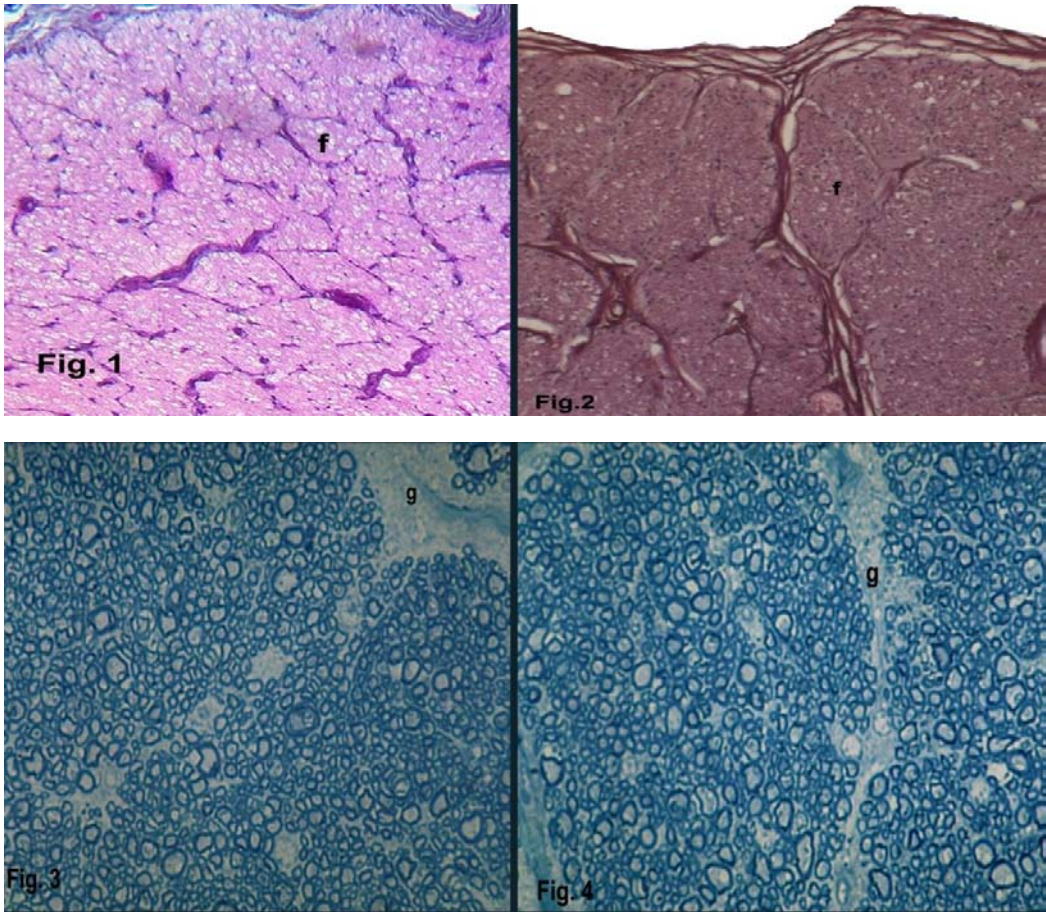


Fig (1): Photomicrograph of cross section of the camel optic nerve as seen with light microscope stained with H& E stain. f: fiber bundles or fascicles X400.

Fig (2): Photomicrograph of cross section of the donkey optic nerve as seen with light microscope stained with H&E stain. f: fiber bundles or fascicles X400.

Fig (3): Light photomicrograph of semithin section (0.5 μ m) of the camel optic nerve stained with 0.3 % toluidine blue. The fibers gathered together into bundles or fascicles separated by glial processes (g). X600

Fig (4): Light photomicrograph of semithin section (0.5 μ m) of the donkey optic nerve stained with 0.3 % toluidine blue. The fibers gathered together into bundles or fascicles separated by glial processes (g). X600

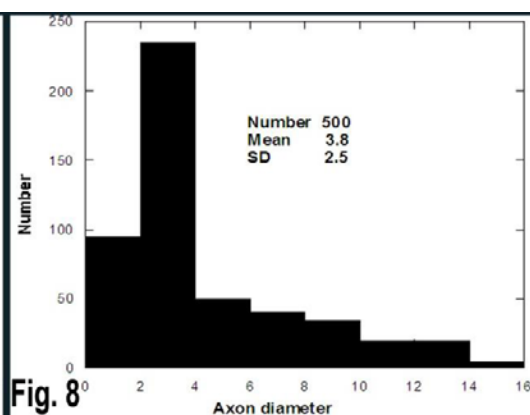
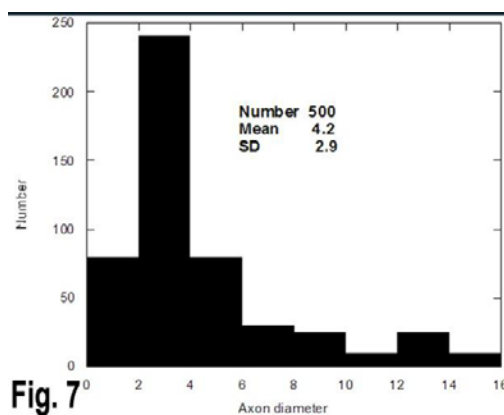
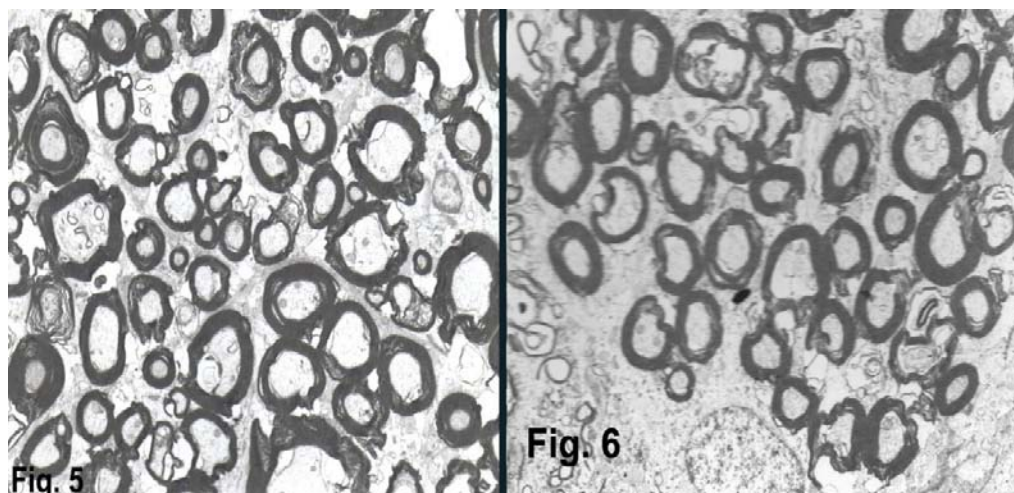


Fig (5): Electron micrograph of an ultrathin section (70 nm) of the camel optic nerve stained with saturated solution of uranyl acetate dehydrate. X2000.

Fig (6): Electron micrograph of an ultrathin section (70 nm) of the donkey optic nerve stained with saturated solution of uranyl acetate dehydrate. X2000.

Fig (7): Histogram showing the axon diameter distribution in the camel optic nerve.

Fig. 8. Histogram showing the axon diameter distribution in the donkey optic nerve.

Table 1 quantitative data of the optic nerve in the camel (*Camelus dromedaries*):-

Specimen	Total cross-section area (mm ²)	Number of sampling area	The sampling area (mm ²)	Estimated total area (mm ²)	Number of fibers counted	Total optic nerve fibers
Right	24.3	100	0.0025	0.32	23330	1145720
Right	25.7	120	0.0025	0.37	26510	1200340
Right	24.9	115	0.0025	0.36	22700	1127500
Left	23.9	150	0.0025	0.30	24100	1170430
Left	26.1	130	0.0025	0.40	23520	1215900
Left	25.4	100	0.0025	0.39	22640	1180050

Table 2 quantitative data of the optic nerve in the donkey (*Equus asinus*):-

Specimen	Total cross-section area (mm ²)	Number of sampling area	The sampling area (mm ²)	Estimated total area (mm ²)	Number of fibers counted	Total optic nerve fibers
Right	18.60	90	0.0025	0.29	19154	490510
Right	20.11	110	0.0025	0.30	20222	500250
Right	19.92	100	0.0025	0.31	21100	495280
Left	18.87	130	0.0025	0.33	19872	510590
Left	21.15	140	0.0025	0.39	21006	480230
Left	18.85	95	0.0025	0.32	19225	497665