

Effect of Experimental Stress Factors on the Testes, Spermatogenesis and Spermatozoa Morphology in *Rattus norvegicus*

¹Akunna, G.G.; ²Obikili, E.N.; ²Anyawu, G.E. and ²Esom, E.A.

¹Department of Anatomy, Faculty of Basic Medical Sciences, Federal University Ndufu Alike Ikwo, Ebonyi State,

Nigeria

²Department of Anatomy, Faculty of Basic Medical Sciences, University of Nigeria, Enugu State, Nigeria

with 9 figures & 6 tables received September, accepted for publication October 2016

Abstract

In this study, we aim to evaluate the effect of stress from niddle injection and oral gavaging on gross anatomical parameters, histology, histochemistry of the testes as well as spermatogenesis and spermatozoa morphology in Wistar Rat. Twenty one male Wistar ratswere divided into three groups. Group A were not exposed to any stress, Group B rats were exposed to needle stress by intraperitoneal treatment with 1 ml/kg body weight of distilled water three times a week and group C rats were treated orally with 1 ml/kg body weight of distilled water three times a week. The protocol lasted for 8 weeks. There were no significant ($p>0.05$) difference in body weight, testis weight and volume, spermatozoa count, spermatozoa motility, spermatogonia, spermato

cyte, spermatid, percentage number of morphologically normal spermatozoa and in the percentage number of sluggish, immotile and morphologically abnormal spermatozoa of rat exposed to stress. These rats showed normal histological and histochemical profiles. Also observed were normal geometric parameters across the groups. The present study has shown that stress from research does not affect the gross, histology, histochemistry of the testes, spermatogenesis and spermatozoa morphology in Wistar Rat (*Rattus norvegicus*).

Keywords: Stress, Infertility, Spermatozoa, Wistar rat

Introduction

The process of reproduction is an essential physiological system necessary for the development and sustenance of species. However, this process can be affected by stress (Coubrough, 1985; Dobson and Smith, 2000).

It has been indicated that handling of laboratory animals may result to an unnecessary stress, which may in turn affect the reproductive potentials in different groups of vertebrates (Greenberg and Wingfield, 1987; Pickering *et al.*, 1987; Campbell *et al.*, 1992; Wolfenson *et al.*, 1995; Contreras-Sanchez *et al.*, 1998; Dobson and Smith, 2000; Rutledge, 2001). Hyperactivation of the hypothalamic-pituitary-adrenal (HPA) axis is a key response of stress in vertebrates. ACTH which is released as a result of excitation of the hypothalamus under stressful condition causes the release of glucocorticoids which in turn affect physiological processes (Dobson and Smith, 1995; Saplosky, 1999).

Environmental stress has also been reported to cause low sperm quality (Coubrough, 1985; Rutledge, 2001).

It is important to note that reactive oxygen species and antioxidant balance is essential to reproductive process. However, a disruption in this balance results to oxidative stress (Agarwal *et al.*, 2005). It has

been noted that stressful situations could lead to oxidative stress due to elevated levels of glucocorticoids, which causes free radical formation (Gao *et al.*, 2003, Inoue, 2003) and subsequently decrease sex steroids synthesis (Monder *et al.*, 1994).

In this study, we aim to evaluate the effect of stress from niddle injection and oral gavaging on gross anatomical parameters, histology, histochemistry of the testes as well as spermatogenesis and spermatozoa morphology in Wistar Rat

Material and Methods

Twenty one male Wistar rats (10 to 12 weeks old) weighing 165-275 g were secured from the animal house of the Department of physiology, University of Nigeria, Enugu Campus. The animals were housed in well ventilated wire cages in the Animal Facility and an ethical approval was obtained from the Ethical Committee on Animal use with reference

NNHREC/05/01/2008b-FWA00002458-1RB00002323.

The rats were divided into three groups of seven rats each. The rats in group A served as the control group and were not exposed to any stress, Group B rats were exposed to needle stress by intraperitoneally treating them with 1 ml/kg body weight of distilled water three times

a week and group C rats were exposed to oral gavage stress by orally treating them with 1 ml/kg body weight of distilled water three times a week. The protocol lasted for 8 weeks (Duration of spermatogenesis in rat being 51.6-56 days).

Animal Sacrifice and Sample Collection

The rats were first weighed and then sacrificed by cervical dislocation. The abdominal cavity was opened up through a midline abdominal incision to expose the reproductive organs. The testes were excised and trimmed of all fat. The testicular weights of each animal were evaluated with an electronic analytical and precision balance (BA 210S, d=0.0001- Sartoriusen GA, Goettingen, Germany). The testes volumes were measured by water displacement method. The two testes of each rat were measured and the average value obtained for each of the two parameters was regarded as one observation. The testes of each animal was fixed in Bouin's fluid for histological and morphometric analysis.

Determination of Epididymal Sperm Parameters

The motility score was estimated using the method described by Akunna *et al.*, 2013. Motility estimates were performed from three different fields in each sample and

their mean was used as the final motility score. The motile spermatozoa were classified as motile, sluggish or non-motile. Spermatozoa in the right epididymis were counted by a modified method of Yokoi and Mayi (2004) while the normal and abnormal spermatozoa morphology was estimated as described by Akunna *et al.*, (2014). Spermatozoa were considered abnormal morphologically if it had rudimentary tail, round head and detached head, headless, curved mid-piece and curved tail.

Tissue Preparation for Histology and Histochemistry

Tissues preparation for histology and histochemistry was done as described previously in our laboratory (Akunna *et al.*, 2013). Sections were stained with H & E and Periodic Acid-Schiff (PAS) reaction with hematoxylin counterstaining, after which they were passed through a mixture of equal concentration of xylene and alcohol. Following clearance in xylene the sections were oven-dried between 35°C and 40°C (Sheehan and Hrapchak, 1987). The slides were viewed under a research microscope connected to a computer monitor for qualitative and quantitative evaluation.

Determination of Morphometric Parameters

For each testis, seven “vertical sections” from the polar and the equatorial regions were sampled (Qin and Lung, 2002). Seven “vertical sections” per testis was selected by a systematic sampling method that ensured fair distribution between the polar and equatorial regions of each testis. Briefly, a section was taken at the equator of each testis; one on each side of the equator, three-quarters of the distance between the pole and the equator; another half-way between each pole and the equator; and one on each side of the equator, a quarter of the distance from each of the pole. Diameter, perimeter, length, Width, roundness, lumen diameter and germinal epithelia height of seminiferous tubules of the testes were estimated with a digimizer software programme.

Unbiased numerical estimation of the following morphometric parameters was determined using a systematic random scheme (Gundersen and Jenson, 1987): Cross-sectional area of the seminiferous tubules (A_C); number of profiles of seminiferous tubules per unit area of testis (N_A); and numerical density of the seminiferous tubules (N_V).

For each stereological parameter (D , A_C , N_A and N_V), five randomly selected fields from all the seven sections of a single testis were viewed, and estimation on each car-

ried out. The average from a total of seventy readings from five fields in seven sections of the two testes of one rat was obtained and this was recorded as one observation. The evaluation of the diameter was done with calibrated eyepiece and stage grids mounted on a light research microscope at X 100 magnification. Estimation of volume density of testicular components and number of seminiferous tubules was done on a computer monitor onto which a graph sheet was superimposed and on which slides were projected from a research light microscope (Olympus).

Cross-sectional area (A_C) of the seminiferous tubules of the testes

The cross-sectional areas of the seminiferous tubules was determined from the formula $A_C = \pi D^2/4$, (where π is equivalent to 3.142 and D the mean diameter of the seminiferous tubules).

Number of profiles of seminiferous tubules in a unit area of testis (N_A)

The Number of profiles of seminiferous tubules per unit area was determined by using the unbiased counting frame proposed by Gundersen (1977) as described by Saalu *et al.*, 2013. Using this frame, in addition to counting profiles completely inside the frame we counted

all profiles with any part inside the frame provided they did not touch or intersect the forbidden line (full-drawn line) or exclusion edges or their extension.

Numerical Density (N_V) of seminiferous tubules

This is the number of profiles per unit volume and was determined by using the modified Floderus equation: $N_V = N_A / (D + T)$ (Gilliland *et al.*, 2001) where, N_A is the number of profiles per unit area, D is the diameter and T the average thickness of the section.

Spermatogenesis

For spermatogenesis, the number of each category of germ cells in stage VII of seminiferous epithelium cycle. All the counts of the germ cells were converted to true counts by the formula, true counts = (crude count \times section thickness) / (section thickness + nuclear diameter of germ cells) (Nirupama and Yajurvedi, 2013).

Statistical Analysis

The data were statistically analyzed and expressed as Mean \pm SD. Analysis was carried out using analysis of variance (ANOVA) with Scheffe's post hoc test. The level of significance was considered at $p < 0.05$ and $P < 0.01$.

Results and Discussion

Body Weight, Testicular weight and Volume

There were no significant ($p > 0.05$) difference in body weight, testis weight and volume of rat exposed to stress (Table 1). Although testicular weight and volume might appear an insignificant result, it has been indicated and associated to male reproductive ability (Saalu *et al.*, 2006, Akingbade *et al.*, 2014, Akunna *et al.*, 2016). It has been suggested that injury to the seminiferous tubules and interstitial cell of leydig cells could lead to loss of about 70% to 80% of testicular mass (Setchell *et al.*, 1998; Creasy, 2003).

Sperm Analysis

In this study, results show a non-significant ($p > 0.05$) difference in spermatozoa count, spermatozoa motility, percentage number of morphologically normal spermatozoa and in the percentage number of sluggish, immotile and morphologically abnormal spermatozoa (headless sperm, rudimentary tail, curved tail, curved mid-piece) in animal models exposed to stress (Table 2-3 and Figs 2-3) when compared to control group (Tables 2,3 and Fig 1).

Sperm cell is one of the common body cells that are susceptible to stress induced oxidative damage. It

has also been reported that adenosine triphosphate (ATP) is an energy source for sperm motility, and its availability may be a limiting factor responsible for loss of sperm motility. This result is also in line with previous reports that demonstrated normal sperm characteristics in control group of rats (Garside and Harvey, 1992; Cai *et al.*, 1997; Lafuente and Esquifino, 2000; Atessahin *et al.*, 2006; Silici *et al.*, 2009). Laskey *et al.*, 1984) also reported normal sperm progressive motility and sperm normality in control group of rat.

Testes Histological, Histochemical and Morphometric Profiles

The rats that were exposed to stress (Fig 4B&C) showed normal histological profiles, with normal interstitium, germinal epithelium and presence of late stage germ cells and sperm bundles when compared to those of the control histological profiles (Figs 4-6).

Histological results also showed a regular cycle of spermatogenesis in these groups. Also the number of spermatogonia, spermatocyte, spermatid and sperm cells in the seminiferous tubules of these animals were comparable to that of the control (Table 5 and Figs 4-6).

The testes of rat exposed to stress had strong PAS-positive materials when compared to the control

group. In these groups, tunica albuginea, the boundaries of the seminiferous tubules as well as the intertubular connective tissue had strong PAS-positive materials (Figs 7-9).

Normal polysaccharides content were observed in control group of rat. Numerous PAS-positive materials appeared in tunica albuginea as well as in the intertubular connective tissue of testes of groups exposed to stress (Figs 7-9).

The mean diameter, perimeter and length of the seminiferous tubules in the negative control rats were $278.5 \pm 2.1\mu\text{m}$, $910.0 \pm 44.0 \mu\text{m}$ and $330.4 \pm 12.0 \mu\text{m}$ respectively (Table 5). The geometric parameters of the test animals were comparable to that of the control. The tubular diameter, perimeter and length of the seminiferous tubules were comparable to the negative control group (Table 5).

The width, roundness and lumen diameter of the seminiferous tubules in the control rats were $231.6 \pm 14.2 \mu\text{m}$, $0.82 \pm 0.1\mu\text{m}$ and $85.1 \pm 1.9 \mu\text{m}$ respectively (Table 6).

The mean number of germinal epithelia height, cross-sectional area, number of profiles per unit area and numerical density of seminiferous tubules in negative control groups were $32.1 \pm 1.8\mu\text{m}$, $22.61 \pm 1.12 \text{Ac}$ ($\times 10^3\mu\text{m}^3$), $26.0 \pm 1.3 \text{N}_A$ ($\times 10^{-8} \mu\text{m}$ -

²) and 13.10 ± 3.2 ($\times 10^{-10} \mu\text{m}^{-2}$) respectively (Table 6). These geometric values were not significantly ($p > 0.05$) different from that of the group exposed to stress (Table 6).

Normal seminiferous tubules and geometric parameters, PAS-negative materials observed in our study are in accordance with several other findings (Xu *et al.*, 1993; Scholzen and Gerdes, 2000; Zhang *et al.*, 2001). Atessahin *et al.*, (2006) provide well-documented evidences of testicular morphology and morphometry of the testes in control animal models (Cherry *et al.*, 2004; Boekelheide *et al.*, 2005).

The geometric parameters in our study are in accordance with several other studies (Caiet *et al.*, 1997; Lafuente and Esquifino, 2000). In the same line, the normal germinal epithelia thickness and seminiferous tubular diameter might be due to normal spermatogenesis, which might have resulted in normal sperm count, motility and normal sperm morphology observed in our study.

Conclusion

The present study has shown that stress from research does not affect the gross, histology, histochemistry of the testes, spermatogenesis and spermatozoa morphology in Wistar Rat.

Conflict of Interest

There were no competing interests among the authors.

Acknowledgments

The authors thank Mr. J.A. Oguntola, Dr. Egwu O.A and Mr. Johnson N to Johnson for their help as regards to this experiment.

References

- Agarwal, A., Gupta, S., Sharma, R.K. (2005):** Role of oxidative stress in female reproduction. *Reprod Biol Endocrinol.* 3: 1-32.
- Akingbade A.M., L.C. Saalu, O.O. Oyebanji, D.A. Oyeniran, O.O. Akande and G.G. Akunna. (2014):** Rhodinol-based incence testiculotoxicity in Albino rats: Testicular histology, Spermatogenic and Biochemical Evaluations. *Journal of Pharmacology and Toxicology*, 9: 68-81.
- Akunna, G.G.; Obikili, E.N.; Anyawu, G.E.; Esom, E.A. (2016):** Spermigraphic, 2 and 3-Dimensional Quantitative Analysis Of Testicular Tissues Of Rat Submitted To Citrus Paradisi Waste Extract And Cisplatin-Induced Cytotoxicity. *International Journal of Cancer Research*, 12:176-187.

- Akunna G.G., Saalu L.C., Ogunlade B., Ojewale A.O., Enye L.A., Ogunmodede S. (2013):** Experimental diabetes using a new model of induction: Histological and Stereo-logical evaluation of the testis post-adminis-tration of Bay Leaf (*Laurus nobilis*) Extract. The Global Journal of Pharmaceutical Research, , 2(1) :1585-1594, 31.
- Akunna G.G, Saalu L.C., Ogunlade B, Enye L.A. (2014):** Spermatotoxicity in Animal Models Exposed to Fragrance Components. Journal of Medical Science. 14 (1): 46-50.
- Atessahin A, Karahan I, Turk G, Gur S, Yilmaz S, Ceribası AO. (2006):** Protective role of lycopene on cisplatin-induced changes in sperm characteristics, testicular damage and oxidative stress in rats. Reprod Toxicol. 21: 42–47.
- Boekelheide, K., Schoenfeld, H. A., Hall, S.J., Weng, C.C. , Shetty, G. and Leith, J. (2005):** Gonadotropin-releasing hormone antagonist (Cetrorelix) therapy fails to protect nonhuman primates (*Macacaarctoides*) from radiation-induced spermatogenic failure. J. Androl. 26: 222- 234.
- Cai, L., Hales, B. and Robaire, B. (1997):** Induction of apoptosis in the germ cells of adult male rats after exposure to Cyclophosphamide. Biol. Reprod. 56: 1490–1497.
- Cherry, S.M; Hunt, P.A, and Has-sold T.J. (2004):** Cisplatin disrupts mammalian spermatogenesis, but does not affect recombination or chromosome segregation. Mutat Res., 564:115-128.
- Compbell, P.M.; Pottinger, T.G. and Sumpter, J.P. (1992):** Stress reduces the quality of gametes produced by Rainbow trout. Bi ol Reprod 47, 1140-1150.
- Contreras-Sanchez, W.M., Schreck, C.B., Fitzpatrick, M.S. and Pereira C.B. (1998):** Effects of stress on the reproductive performance of rainbow trウト (*Oncorhynchus mykiss*).Biol Reprod 58: 439-447.
- Coubrough, R.I. (1985):** Stress and Fertility. A Review. Onderstepoort Journal of Veterinary Research, 52: 153-156.
- Creasy, D.M. (2003):** Evaluation of testicular toxicology: A synopsis and discussion of the recommendations proposed by the Society of Toxicologic Pathology. Birth Defects Research Part B: Dev. Reproductive Toxicology, 68: 408-415.
- Dobson, H. and Smith, R.F. (1995):** Stress and Reproduction in Farm Animals. *Journal of Reproduction and Fertility.Supplement*, 49: 451-461

- Dobson, H. and Smith, R.F. (2000):** What Is Stress, and How Does It Affect Reproduction? *Animal Reproduction Science*, 2: 743-752. [http://dx.doi.org/10.1016/S0378-4320\(00\)00080-4](http://dx.doi.org/10.1016/S0378-4320(00)00080-4)
- Gao, H.B.; Tong, M.H. and Hu, Y.Q. (2003):** Mechanisms of glucocorticoid-induced Leydig cell apoptosis. *Mol Cell Endocrinol*; 199: 153-163.
- Garside DA, Harvey PW. (1992):** Endocrine toxicology of the male reproductive system. In: Atterwill CK, Flack JD, editors. *Endocrine Toxicology*. Cambridge: Cambridge University Press : 285-312.
- Gilliland, K.O.; Freel, C.D.; Lane, C.W., Fowler, W.C. and Costello, M.J. (2001):** Multilamellar bodies as potential scattering particles in human age-related nuclear cataracts. *Molecular Vision*, 7: 120-130.
- Greenberg, N. and Wingfield, J. (1987):** Stress and reproduction: reciprocal relationships. In: Norris DO, Jones RE, editors. *Hormones and reproduction in fishes, amphibians and reptiles*, New York: Plenum Press. Pp. 461-503.
- Gundersen, H.J.G. (1977):** Notes on the edge of the numerical density of arbitrary profiles: the edge effect. *J Microsc*, 111: 219-223.
- Gundersen, H.J.G. and Jenson, E.B. (1987):** The efficiency of systematic sampling in stereology and its prediction. *J Microsc.*, 147, 229-263.
- Inoue, M. (2003):** Mitochondrial generation of reactive oxygen species and its role in aerobic life. *Current Med Chem*. 10: 2495-2505.
- Lafuente, A. and Esquifino, A.I. (2000):** Cadmium effects on hypothalamic activity and pituitary hormone secretion in the male. *Toxicol Lett*. 110:209–218.
- Laskey, J.W., Rehnberg, G.L., Laws, S.C., Hein, J.F. (1984):** Reproductive effects of low acute doses of cadmium chloride in adult male rats. *Toxicol Appl Pharmacol*. 73:250–255.
- Monder C, Miroff Y, Marandici A, (1994):** 11beta-hydroxysteroid dehydrogenase alleviates glucocorticoid-mediated inhibition of steroidogenesis in rat Leydig cells. *Endocrinology*; 134: 1199-204.
- Nirupama M. and Yajurvedi H. N. Durational (2013):** Effects of chronic stress on the testicular damage and itsreversibility in albino rat. *European Journal of Experimental Biology*, , 3(5): 229-239.
- Pickering, A.D.; Pottinger, T.G.; Carragher, Sumpter, P. (1987):**

The effects of acute and chronic stress on the levels of reproductive hormones in the plasma of mature male brown trout, *salmo trutta*. *Gen Comp Endocrinol*, 68: 249-259.

Qin, D. and Lung, M.A. (2002): Morphometric study on Leydig cells in capsulotomized testis of rats. *Asian J Androl*, 4: 49-53.

Rutledge, J.J. (2001): Use of Embryo Transfer and IVF to Bypass Effects of Heat Stress. *Theriogenology*, 55: 105-111.

Saalu, L.C.; Togun, V.A.; Oyewopo, A.O. and Raji, Y. (2006): Artificial cryptorchidism and the moderating effect of melatonin (N – acetyl, 5 – methoxytryptamin) in Sprague Dawley Rats. *Journal of Applied Sciences*, 6 (14): 2889-2894.

Saalu, L. C.; Akunna, G. G., Oyewopo, A. O. (2013): The histomorphometric evidences of *Vernonia amygdalina* leaf extract-induced testicular toxicity. *International Journal of Morphology*, 31(2): 662-667.

Saplosky, R.M. (1999): Glucocorticoids, stress, and their adverse neurological effects: relevance to aging. *Exp Gerontol* 34: 721–732

Scholzen, T. and Gerdes, J. (2000): The Ki-67 protein: from the

known and the unknown. *J Cell Physiol*. 182: 311–322.

Setchell, B.P. and Brooks, D.E. (1998): Anatomy, vasculature, innervations and fluids of the male reproductive tract. In: Knobil, E., and Neil, J.D., eds *The physiology of Reproduction*. New York, NY; Raven. : 753–836.

Sheehan, D.C. and Hrapchak, B.B. (1987): Theory and practice of histotechnology, 2nd Edition. Columbus: Battelle Memorial Institute: 39-40.

Silici, S.; Ekmekcioglu, O.; Eraslan, G. and Demirtas, A. (2009): Antioxidative effect of royal jelly in cisplatin-induced testes damage. *Urology*, 74 (3): 545-551.

Wolfenson, D., Thatcher, W.W.; Badinga, L.; Sovio, J.D.; Meidan, R.; Lew, B.J.; Brawtal, R. and Berman, A. (1995): Effect of heat stress on follicular development during the estrous cycle in lactating dairy cattle. *Biol Reprod*. 52: 1106–1113.

Xu, B.; Chin, S.E.; Tsakak, M. and Ong, C.N. (1993): Trace elements in blood and seminal plasma and their relationship to sperm quality. *Reprod. Toxicol*. 7: 613-618.

Yokoi, K. and Mayi, Z. K. (2004):
Organ apoptosis with cytotoxic
drugs. Toxicology, 290: 78 –85.

**Zhang, X.; Yamamoto, N.; Sora-
moto, S. and Takenaka, I. (2001):**
Cisplatin-induced germ cell apopto-
sis in mouse testes. Arch. Androl.
46: 43-49.

Corresponding author

Akunna G.G

+23408038619526

Research ID: K-5505-2016

ORCID: 0000-0001-6476-4657

ggakunna@gmail.com

Table (1): The Effects of stress from needle piercing and oral gavaging on body weight, testicular weight and testes volume of Male Rats.

Groups	Initial Body Weight (g)	Final Body Weight (g)	Body Weight Diff.	Testes Weight (g)	Testes Volume (ml)	Testes Weight/Body Weight Ratio
A	238.1±15.5	327.8 ±39.7	89.7	1.6 ± 0.2	1.5±0.2	0.004
B	274.5 ± 1.7 [*]	300.1±1.9 [*]	25.6 [*]	1.5 ± 0.2 [*]	1.0±0.2 [*]	0.004 [*]
C	270.1±2.0 [*]	314.3±2.1 [*]	44.2 [*]	1.7±0.5 [*]	0.8±2.3 [*]	0.004 [*]

^{*}represent non-significant increases or decreases at $p > 0.05$ when compared to negative control (Group A). Values are means ± SD. n = 7 in each group.

Table (2): Effects stress from needle piercing and oral gavaging on sperm count, motility and morphology in Wistar rats.

Groups	Sperm count ($10^6/ml$)	Motility (%)	Sluggish (%)	Immotile (%)	Headless Sperm(%)
A	134.2±9.9	76.1±1.4	18.1±1.4	21.3±0.8	9.0±2.6
B	130.0±2.9 [*]	68.6 ± 1.7 [*]	20.4±2.1 [*]	25.7±1.2 [*]	12.1±4.1 [*]
C	123.4±2.1 [*]	81.5±2.8 [*]	21.4±2.1 [*]	29.2±0.5 [*]	8.3±1.9 [*]

^{*}represent non-significant increases or decreases at $p > 0.05$ when compared to negative control (Group A). Values are means ± SD. n = 7 in each group.

Table (3): Effects of stress from needle piercing and oral gavaging on sperm morphology of Wistar rats.

Groups	Rudimen- tary Tail (%)	Curved piece (%)	Mid- Curved tail (%)	Total ab- normal (%)	Total nor- mal (%)	Total cell counted (%)
A	8.1±1.1	13.7±0.1	7.2±1.1	38±3.2	521.2±0.1	555.5±0.7
B	10.4±1.7*	14.9±5.0*	7.1±2.3*	45.5±3.0*	335.2±0.4*	435.4±1.1*
C	8.3±0.2*	10.3±0.1*	9.3±4.3*	36.2±5.1*	311.2±9.1*	416.6±2.0*

*represent non-significant increases or decreases at $p > 0.05$ when compared to negative control (Group A). Values are means \pm SD. n = 7 in each group.

Table (4): Effects of stress from needle piercing and oral gavaging on type A spermatogonia, preleptotene spermatocyte, midpachytene spermatocyte, round spermatids and elongated spermatids in Wistar rats.

Groups	Type A Spermatogonia	Preleptotene spermatocyte	Midpachytene spermatocyte	Round spermatids	sper-Elongated spermatids
A	5.21±2.1	12.3±1.1	32.0±3.1	103.0±1.1	130.01±2.1
B	4.8±3.5*	14.6±6.0*	32.1±6.1*	107.1±4.1*	137.33±3.2*
C	6.1±2.0*	12.1±6.1*	29.8±3.1*	103.0±2.1*	131.01±1.3*

*represent non-significant increases or decreases at $p > 0.05$ when compared to negative control (Group A). Values are means \pm SD. n = 7 in each group.

Table (5): Effects of stress from needle piercing and oral gavaging on Diameter (D), perimeter of seminiferous tubules (PST) cross-sectional area (Ac), number of profiles per unit area (N_A) and length of seminiferous tubules (LST) of Wistar rats.

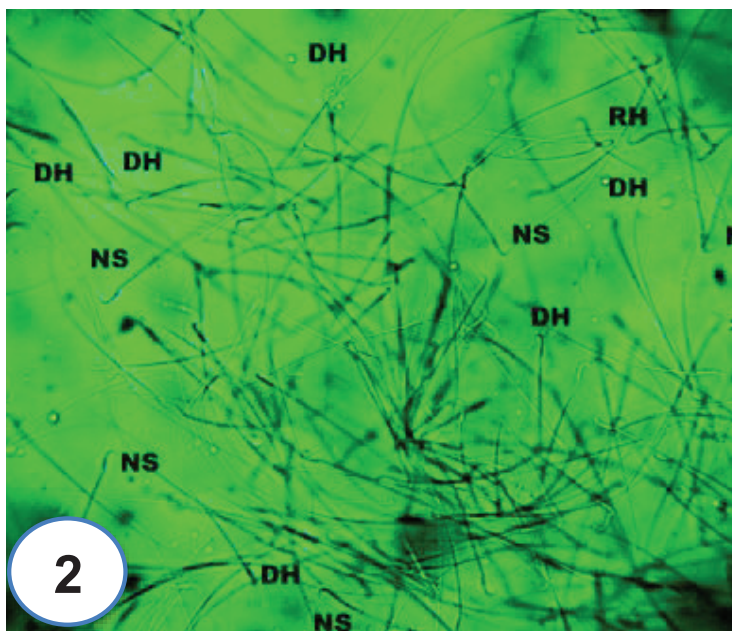
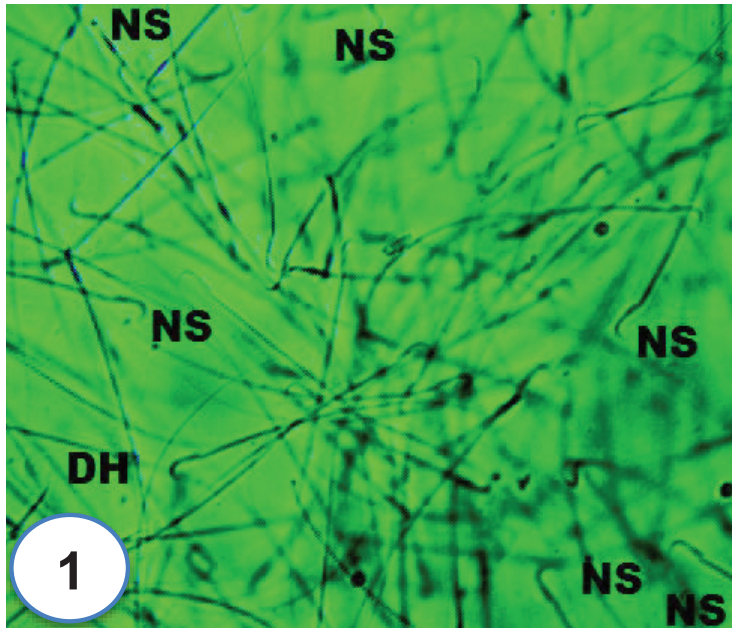
Treatment Groups	D (μm)	PST (μm)	Ac (x 10 ³ μm ²)	N _A (x10 ⁻⁸ μm ⁻²)	LST (μm)
GROUP A	278.5 ± 2.1	910.0 ± 44.0	22.61 ± 1.12	26.0 ± 1.3	330.4 ± 12.0
GROUP B	270.2 ± 4.2 [*]	911.9 ± 14.1 [*]	20.53 ± 1.2 [*]	23.3 ± 6.1 [*]	328.7 ± 41.2 [*]
GROUP C	273.1 ± 7.2 [*]	915.7 ± 21.0 [*]	21.31 ± 3.4 [*]	27.1 ± 4.3 [*]	329.1 ± 6.3 [*]

^{*}represent non-significant increases or decreases at p > 0.05 when compared to negative control (Group A). Values are means ± SD. n = 7 in each group.

Table (6): Effects of stress from needle piercing and oral gavaging on width (WST), roundness (RST) germinal height (GEH), numerical density (N_v) and lumen diameter (LD) of seminiferous tubules of Wistar rats.

Treatment Groups	WST (μm)	RST (μm)	GEH (μm)	N _v (x10 ⁻¹⁰ μm ⁻²)	LD (μm)
GROUP A	1.6 ± 14.2	0.82 ± 0.1	32.1 ± 1.8	13.10 ± 3.2	85.1 ± 1.9
GROUP B	2.1 ± 18.1 [*]	0.80 ± 0.1 [*]	33.6 ± 3.5 [*]	10.01 ± 3.3 [*]	81.3 ± 9.6 [*]
GROUP C	3.2 ± 12.3 [*]	0.84 ± 0.1 [*]	32.1 ± 4.1 [*]	12.11 ± 3.1 [*]	81.1 ± 1.1 [*]

^{*}represent non-significant increases or decreases at p > 0.05 when compared to negative control (Group A). Values are means ± SD. n = 7 in each group.



Figs (1&2): (From Left): Sperm Morphology of control rats and rats exposed to stress from needle piercing for 8 weeks. RH: Round head, DH: Detached, Double tail, NS: Normal sperm. Magnification: x 100.

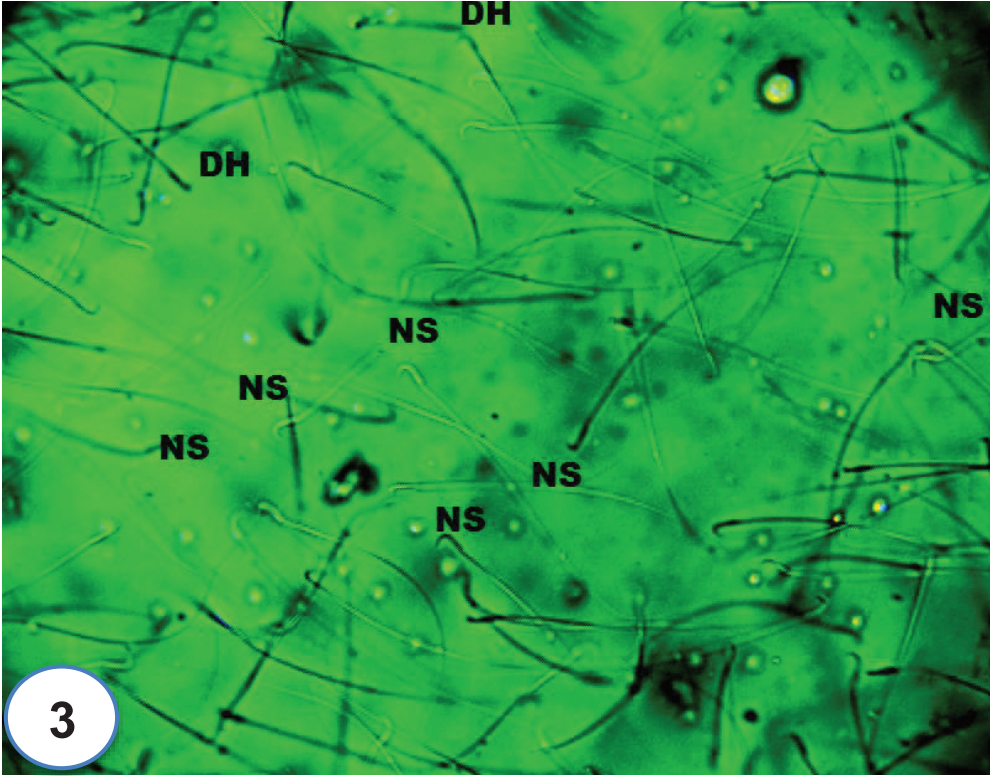


Fig (3): Sperm Morphology of rat exposed to stress from oral gavaging for 8 weeks DH: Detached, Double tail, NS: Normal sperm. Magnification: x 100.

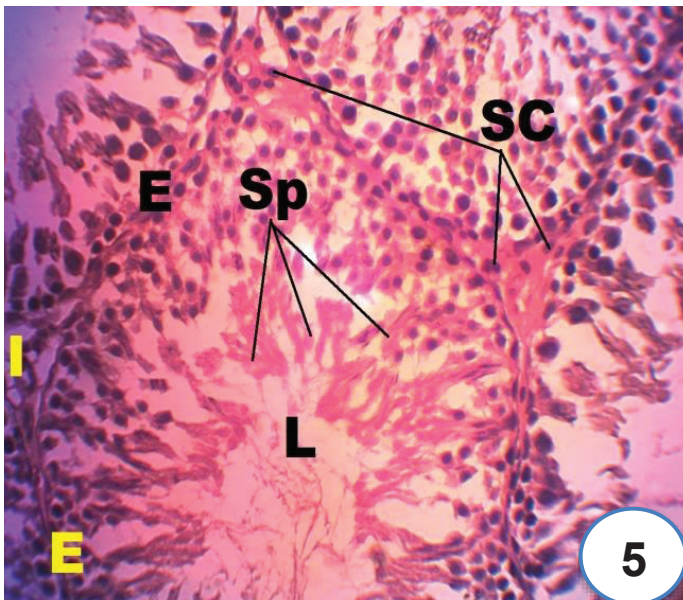
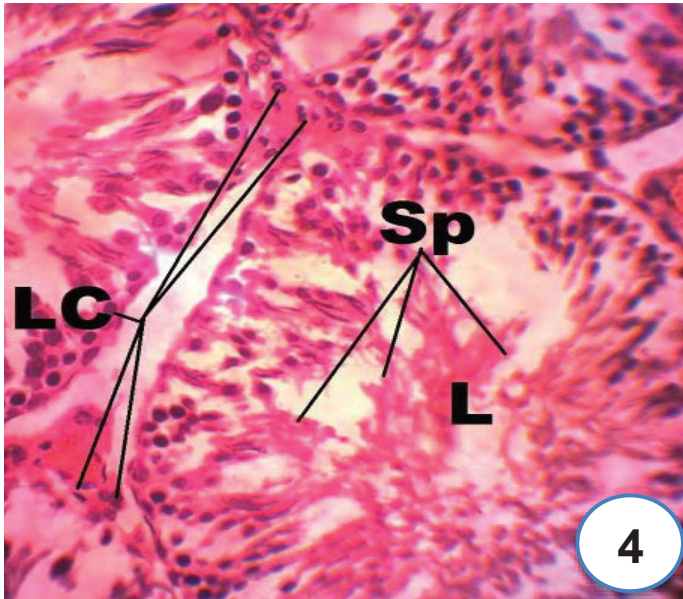


Fig (4&5): (From Left): Histological micrograph of a cross-section of testis of group A rats and group B (Stress from needle piercing) for 8 weeks. Stain: H&E. Slide showing the seminiferous tubules; L: Lumen; E: Epithelium; SC: Sertoli cells, Sp: Spermatozoa, LC: Leydig cells. Stain: haematoxylin and eosin. Magnification: x 400.

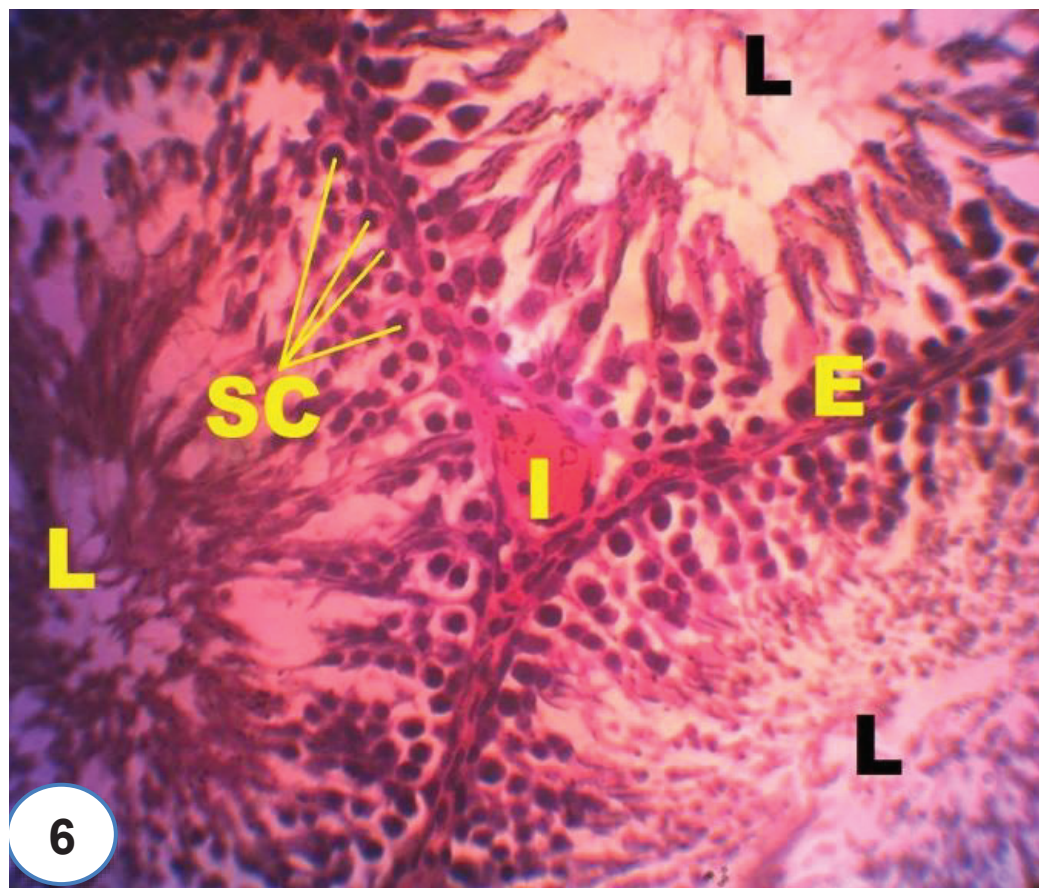
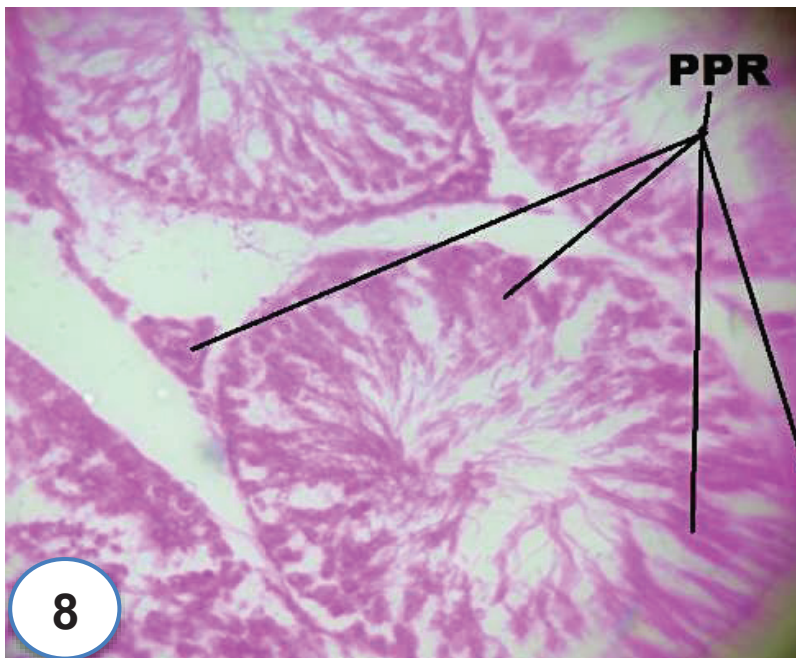
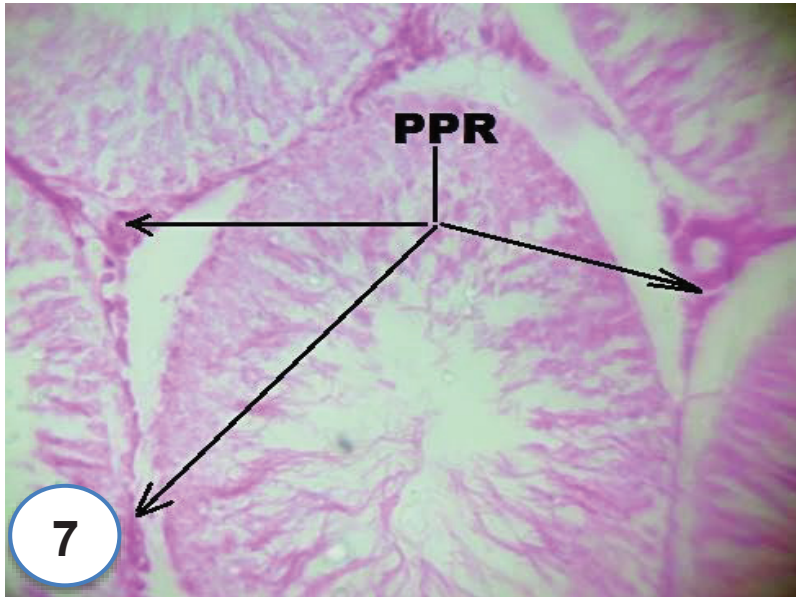


Fig (6): Histological micrograph of a cross-section of testis of group C (Stress from oral gavaging) for 8 weeks. Stain: H&E. Slide showing the seminiferous tubules; L: Lumen; E: Epithelium; SC: Sertoli cells. Stain: haematoxylin and eosin; Magnification: x 400.



Figs (7&8): (From Left) Histochemical micrograph of a cross-section of testis of group A rat and group B (Stress from needle piercing) for 8 weeks. Stain: H&E. Slide showing the seminiferous tubules. PPR: PAS positive reactions. Stain: PAS; Magnification: x 400.

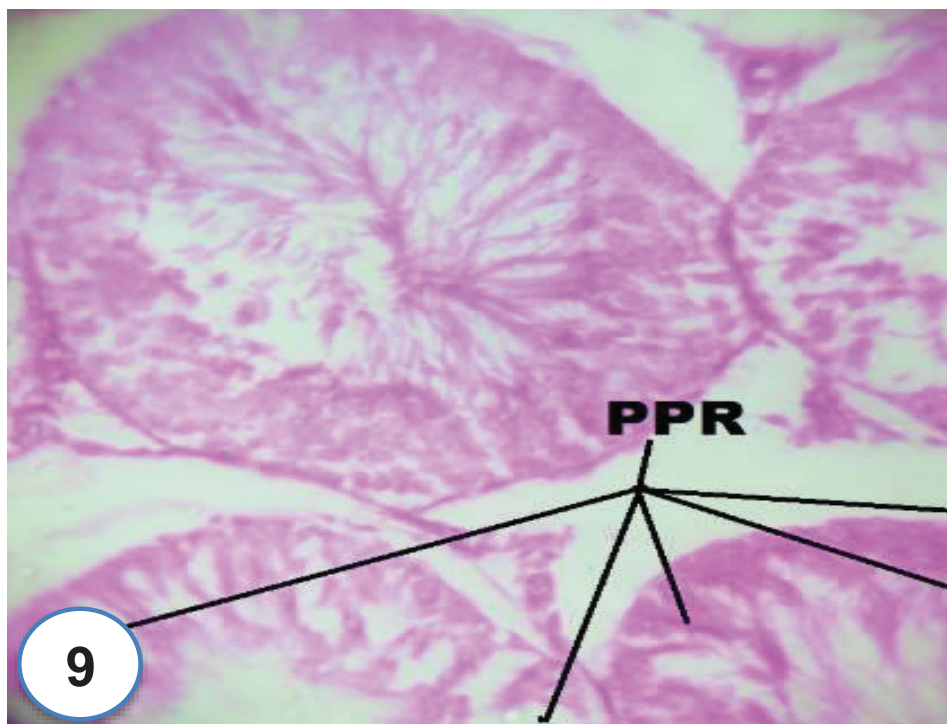


Fig (9): Histochemical micrograph of a cross-section of group C (Stress from oral gavaging) for 8 weeks. Stain: H&E. Slide showing the seminiferous tubules;. PPR: PAS positive reactions. Stain: PAS; Magnification: x 400.